

## Thyroid Hemiagenesis Accompanying a Thyroglossal Duct Cyst: a Case Report

Jabri M \*, Hamza G, Moussafir A, Loudghiri M, Bijou W, Oukessou Y, Rouadi S, Abada R, Roubal M and Mahtar M

Department of Otolaryngology, Head and Neck Surgery, Ibn Rochd University Hospital, Faculty of Medicine and Pharmacy, Hassan II University, Casablanca, Morocco

**Citation:** Jabri M, Hamza G, Moussafir A, et al. Thyroid Hemiagenesis Accompanying a Thyroglossal Duct Cyst: a Case Report. *Medi Clin Case Rep J* 2024;2(4):514-516. DOI: doi.org/10.51219/MCCRJ/Meryeme-Jabri/137

**Received:** 05 October, 2024; **Accepted:** 15 October, 2024; **Published:** 17 October, 2024

\***Corresponding author:** Meryeme Jabri, Department of Otolaryngology, Head and Neck Surgery, Ibn Rochd University Hospital, Faculty of Medicine and Pharmacy, Hassan II University, Casablanca, Morocco, Email: jabrimeryeme2@gmail.com

**Copyright:** © 2024 Jabri M, et al., This is an open-access article distributed under the terms of the Creative Commons Attribution License, which permits unrestricted use, distribution, and reproduction in any medium, provided the original author and source are credited.

### ABSTRACT

Thyroid hemiagenesis (TH) is a rare thyroid pathology characterized by the deficient development of a single thyroid lobe or both a thyroid lobe and the isthmus, which was first reported by Handfield-Jones in 1866. Thyroid hemiagenesis is usually identified incidentally with imaging techniques for the investigation of thyroid hormone disorders or evaluation of other complaints. In this case report, we present the case of a 7-year-old female patient presented for a thyroglossal duct cyst revealing an hemithyroid agenesis.

### Introduction

Thyroid hemiagenesis is a rare thyroid pathology characterized by the deficient development of a single thyroid lobe or both a thyroid lobe and the isthmus, which was first reported by Handfield-Jones in 1866<sup>1</sup>.

Thyroid hemiagenesis is usually identified incidentally with imaging techniques for the investigation of thyroid hormone disorders or evaluation of other complaints. A prevalence study with Ultrasonography has indicated an incidence of 0.05%<sup>1,2</sup>. We aimed to present a thyroid hemiagenesis case incidentally diagnosed by neck ultrasonography, who presented with a suspicion of thyroglossal duct cyst.

### Case Presentation

We present the case of a 7 years old female, with no medical history, who consulted for the recurrence of an anterior cervical

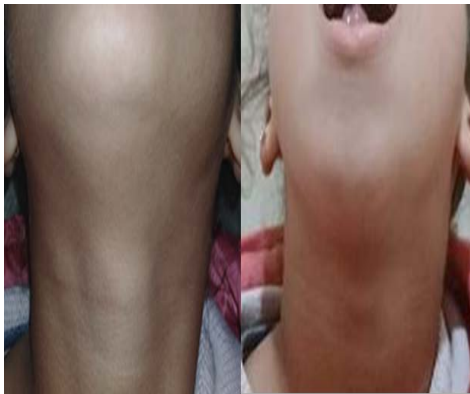swelling occurring for 2 years prior to the diagnosis.

Clinical examination revealed an anterior painless cervical mass, mobile with tongue propulsion, with no signs of inflammation (**Figure 1**). The diagnosis of a thyroglossal duct cyst was evoked, following which a cervical ultrasonography was performed which, in addition to confirming the diagnosis, revealed an agenesis of the left thyroid lobe with doubt about a cystic formation in the left lobe region. (**Figure 2**).

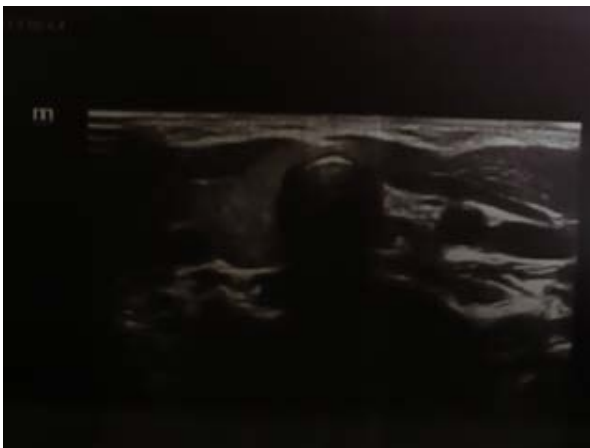A cervical CT scan was performed to confirm the ultrasonography findings, which confirmed the agenesis of the left thyroid lobe and the presence of thyroglossal duct cyst measuring 19.5 x 11 mm with no other abnormalities. (**Figure 3**).

A technetium 99m pertechnetate scan was performed,

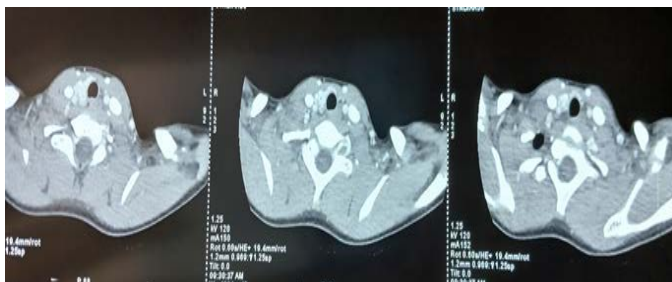which ruled out the presence of an ectopic thyroid gland. TSH level was normal. The patient underwent a modified Sistrunk procedure with resection of the median portion of the hyoid bone without resection of a portion of the musculature of the base of the tongue. Post-operative period was uneventful and the patient was discharged on the second post-operative day (**Figure 4**).



**Figure 1:** Clinical examination revealing an anterior cervical mass mobile with tongue propulsion.



**Figure 2:** Cervical ultrasonography revealing the agenesis of the left thyroid lobe.

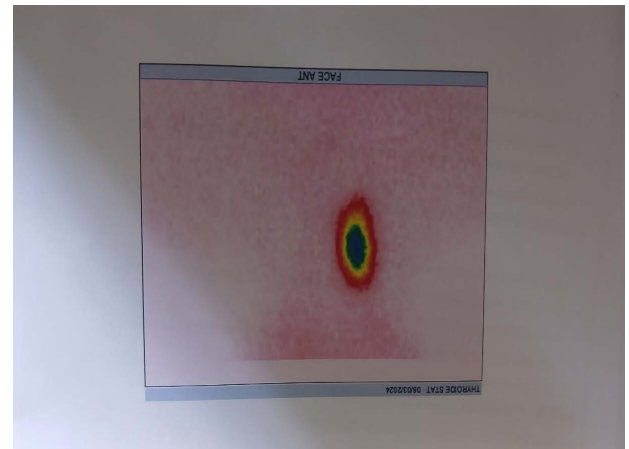


**Figure 3:** The cervical CT-Scan confirming the agenesis of the left thyroid lobe with a normal aspect of the right lobe and the isthmus.

**Discussion**

Thyroid hemiagenesis is a rare congenital disorder in which 1 lobe of the thyroid gland fails to develop while the other lobe, with or without an isthmus, develops normally. It has no pathologic significance until some hormonal dysfunction or hypertrophy affects the existing lobe. The true prevalence of this abnormality is uncertain since the diagnosis is usually made in a population evaluated for other coincidental thyroid diseases<sup>3,4</sup>. This condition was first described by Handfield-Jones in 1886<sup>5</sup> and then by Marshall in 1895 who found 1 case in 60 autopsies<sup>6</sup>. In 1981, Melnick and Stemkowski described the “hockey

stick sign” of thyroidal hemiagenesis on sonography<sup>7</sup>. The incidental discovery rate of thyroidal hemiagenesis by imaging ranges from 1 in 1700 according to Maganini and Narendran<sup>8</sup> to 4 in 7000 according to Hamburger and Hamburger<sup>9</sup>. In an ultrasonographic study of 71 500 patients, Mikosh found 16 cases of thyroid hemiagenesis<sup>1</sup>. This condition seems to nearly always involve the left lobe<sup>3</sup>.



**Figure 4:** Technetium 99m pertechnetate scan ruled out any ectopic thyroid gland and confirmed the left thyroid lobe agenesis.

Thyroglossal duct cyst represents the most common congenital cervical anomaly. It may occur anywhere along the embryologic route of the thyroglossal tract. Most thyroglossal cysts are located between the hyoid and thyroid cartilage (70%) and the rest are located in a suprahyoid position on the floor of the mouth or at the base of the tongue. Ectopic thyroid tissue occurs in 62% of thyroglossal duct remnants and malignant transformation is possible just as in the thyroid gland.

Most patients with thyroid hemiagenesis present with unrelated thyroid symptoms. It is interesting to note that most cases have an agenesis of the left lobe (80% of cases) followed by the isthmus (44-50% of cases). Hyperthyroidism has been reported to be the most common clinical presentation leading to an incidental diagnosis of the hemiagenesis multi-nodular goiter has been reported as the second most common association<sup>10</sup>. However, the association of thyroglossal duct cyst and the thyroid hemiagenesis seems to be uncommon as was only reported in few cases in the literature<sup>11-13</sup>.

The diagnosis of thyroid hemiagenesis can be suggested by a thyroid scintigram which shows accumulation of tracer on one side within the thyroid region. However, caution needs to be exercised for such finding, as there are several conditions, which may mimic hemiagenesis such as autonomous functioning nodule with suppressed normal thyroid tissue, infiltrative disease such as amyloidosis, primary and secondary neoplasm and unilateral inflammation. Correlation with an initial high frequency ultrasonographic examination, which is widely available, is advisable<sup>10</sup>. There is no consensus about the optimal therapeutic strategy for TH perhaps due to the rarity of this clinical entity. It is a matter of debate whether TH should be considered clinically insignificant or whether the absence of one lobe regularly predisposes a patient to the development of clinically important thyroid disease that requires therapy<sup>14</sup>. This dilemma is nearly impossible to resolve, considering that the long-term clinical outcome of this anomaly has not been fully studied<sup>14</sup>. Clinical and biochemical presentation of TH are highly

variable. Although patients with TH may have normal thyroid function, thyroid dysfunction was reported in 38% to 47% of all TH cases. Therefore, these patients need careful follow up. Ruchala et al<sup>15</sup>. recommended that patients with TH should be followed up because thyroid pathologies are likely to develop and all patients with elevated TSH levels should be treated with levothyroxine.

## Conclusion

Thyroid hemiagenesis is a rare developmental anomaly of unknown etiology, typically identified incidentally through imaging techniques.

Preoperative diagnosis is essential in preventing unnecessary surgical interventions. This condition may be associated with various abnormalities, including dysthyroidism or malignancy. In our case, thyroid hemiagenesis was incidentally discovered in conjunction with a thyroglossal duct cyst, an uncommon association. Further follow-up is needed to assess the impact of thyroid hemiagenesis on hormone levels.

**Conflict of Interest:** The authors have no conflicts of interest to declare.

## References

1. Mikosch P, Gallowitsch HJ, Kresnik E, Molnar M, Gomez I, Lind P. Thyroid Hemiagenesis in an Endemic Goiter Area Diagnosed by Ultrasonography: Report of Sixteen Patients. *Thyroid*. nov 1999;9(11):1075-1084.
2. Maiorana R, Carta A, Floriddia G, Leonardi D, Buscema M, Sava L, et al. Thyroid hemiagenesis: prevalence in normal children and effect on thyroid function. *J Clin Endocrinol Metab* avr 2003;88(4):1534-1536.
3. Canani FB, Dall'Olio D, Chiarini V, Casadei GP, Papini E. Papillary carcinoma of a thyroglossal duct cyst in a patient with thyroid hemiagenesis: effectiveness of conservative surgical treatment 2008;14(4):465-469.
4. Yankov YG, Stoev L, Dimanov S, Stoeva M, and Stanislavova K. A Rare Case of Papillary Thyroid Carcinoma in the Thyroglossal Duct Cyst of a 14-Year-Old Female Patient with Left Thyroid Hemiagenesis. *Disponibile surg* 2023;15(11):49712.
5. Henle, Jacob. Wellcome Collection. *Handbuch der systematischen Anatomie des Menschen / von J. Henle*. Disponible surg 3:1855-1871.
6. Marshall CF, Variations in the Form of the Thyroid Gland in Man. *Disponibile sur* 1895;29(2):234-239.
7. Melnick JC, Stemkowski PE. Thyroid Hemiagenesis (Hockey Stick Sign): A Review of the World Literature and a Report of Four Cases. *The Journal of Clinical Endocrinology and Metabolism*. 1 févr 1981;52(2):247-251.
8. Ferrari CC, Lorenz K, Dionigi G, Dralle H. Surgical strategy for primary hyperparathyroidism with thyroid hemiagenesis. *Disponibile sur* 2014 ;8 :1077-1081.
9. Hamburger JI, Hamburger SW. Thyroidal Hemiagenesis: Report of a Case and Comments on Clinical Ramifications. *Archives of Surgery* 1mars 1970;100(3):319-320.
10. 10. Bhartiya S, Verma A, Basu S, Shukla V. Congenital thyroid hemiagenesis with multinodular goiter. *Acta Radiol Short Rep* 2014;3(9):2047981614530286.
11. Dhingra S, Juneja R, Tigga A. Papillary Carcinoma of Thyroglossal Cyst with Thyroid Hemiagenesis: Is Conservative Surgical Management Enough? *Indian J Otolaryngol Head Neck Surg* 2022;74(2):199-205.
12. Yankov YG, Stoev L, Dimanov S, Stoeva M, Stanislavova K. A Rare Case of Papillary Thyroid Carcinoma in the Thyroglossal Duct Cyst of a 14-Year-Old Female Patient with Left Thyroid Hemiagenesis. *Cureus*. nov 2023;15(11):49712.
13. Tsang SK, Maher J. Thyroid hemiagenesis accompanying a thyroglossal duct cyst: a case report. *Clin Nucl Med*. avr 1998;23(4):229-232.
14. De Sanctis V, Soliman AT, Di Maio S, Elsedfy H, Soliman NA, Elalaily R. Thyroid Hemiagenesis from Childhood to Adulthood: Review of Literature and Personal Experience. *Pediatr Endocrinol Rev*. mars 2016;13(3):612-619.
15. Ruchala M, Szczepanek E, Szaflarski W, Moczko J, Czarnywojtek A, Pietz L, et al. Increased risk of thyroid pathology in patients with thyroid hemiagenesis: results of a large cohort case-control study. *Eur J Endocrinol*. 2010;162(1):153-160.