

World Journal of Surgery and Surgical Case Reports

<https://urfpublishers.com/journal/surgery-and-surgical-case-reports>

Vol: 1 & Iss: 1

Comparative Study of Fine Needle Aspiration Cytology and Histopathology Results of Salivary Gland Swelling in St. Paul's Hospital Millennium Medical College, Addis Ababa, Ethiopia

Mohammedsefa Arusi Dari^{1*}, Zeyneb Saleh Hassen² and Zelalem Tadesse Wondimu³

¹Department of Otolaryngology Head and Neck Surgery, Addis Ababa University, Addis Ababa, Ethiopia

²General Practitioner, St. Paul's Hospital Millennium Medical College, Addis Ababa, Ethiopia

³Department of Internal Medicine, Wolkite University, Wolkite, Ethiopia

Citation: Dari MA, Hassen ZS, Wondimu ZT. Comparative Study of Fine Needle Aspiration Cytology and Histopathology Results of Salivary Gland Swelling in St. Paul's Hospital Millennium Medical College, Addis Ababa, Ethiopia. *World J Surg Surgical Case Rep*, 2025;1(1):01-09.

Received: 01 March, 2025; **Accepted:** 01 April, 2025; **Published:** 03 April, 2025

***Corresponding author:** Mohammedsefa Arusi Dari, Department of Otolaryngology Head and Neck Surgery, Addis Ababa University, Addis Ababa, Ethiopia, E-mail: madyamxperia@gmail.com

Copyright: © 2025 Dari MA, et al., This is an open-access article published in World J Surg Surgical Case Rep and distributed under the terms of the Creative Commons Attribution License, which permits unrestricted use, distribution, and reproduction in any medium, provided the original author and source are credited.

ABSTRACT

Background: Fine-Needle Aspiration Cytology (FNAC) is a widely accepted, safe, and cost-effective diagnostic tool for evaluating salivary gland swellings. It helps differentiate between benign, inflammatory, and malignant lesions, aiding in surgical planning and management.

Objective: This study aimed to compare FNAC results with histopathology findings to assess the diagnostic accuracy of FNAC in evaluating salivary gland swellings at St. Paul's Hospital Millennium Medical College, Addis Ababa, Ethiopia.

Methods: A four-year hospital-based cross-sectional study was conducted on patients with salivary gland swellings who underwent both FNAC and histopathology at St. Paul's Hospital Millennium Medical College from January 1, 2019, to August 30, 2022. Data were collected using a standardized questionnaire and analyzed using SPSS version 27. Sensitivity, specificity, Positive Predictive Value (PPV), Negative Predictive Value (NPV), and accuracy were calculated using histopathology as the gold standard.

Results: Of the 475 FNACs performed, 110 cases had correlating histopathology results. The parotid gland was the most commonly affected site (46.4%), followed by the submandibular gland (42.7%) and minor salivary glands (10.9%). FNAC demonstrated high sensitivity, specificity, and accuracy: 100%, 98.83%, and 99.09% for non-neoplastic lesions; 96.4%, 92.6%, and 94.5% for benign neoplasms; and 83.3%, 95.5%, and 94.54% for malignant neoplasms, respectively.

Conclusion: FNAC is a highly sensitive and specific diagnostic tool for evaluating salivary gland swellings. It is reliable for preoperative planning and can help avoid unnecessary surgical interventions.

Keywords: Salivary gland, Fine needle aspiration cytology, Histopathology, Diagnostic accuracy

1. Introduction

1.1. Background of the study

Salivary gland swellings can result from tumors, inflammatory processes, or cysts. Salivary gland tumors account for approximately 3% of all head and neck malignancies, with the majority of these neoplasms being benign^{1,2}. Malignant salivary gland tumors represent only 20% of cases, and the annual incidence of salivary gland cancers is reported to be 0.5 to 2 per 100,000 people. These tumors affect both men and women equally, with the majority of cases occurring in the sixth decade of life³. Tumors can develop in both the major and minor salivary glands, with the parotid glands accounting for 80% of major salivary gland tumors, while the palate is the most common site for minor salivary gland tumors⁴.

Clinical practice has shown that the smaller the salivary gland, the more likely the tumor is malignant. Around 20% to 25% of tumors in the parotid glands are malignant, while this percentage increases to 40% in the submandibular glands, and over 90% of sublingual gland tumors are malignant^{3,5}. The parotid gland accounts for 75% of salivary gland tumors, while the submandibular glands contribute 25%. Minor salivary glands and the sublingual glands account for 8% and 1%, respectively. The most common benign tumor is pleomorphic adenoma, which is predominantly of parotid gland origin. Among malignant tumors, mucoepidermoid carcinoma is the most common, while adenoid cystic carcinoma is the most common malignant tumor in the submandibular and minor salivary glands⁶.

Non-neoplastic lesions of the salivary glands are often caused by chronic sialadenitis, followed by retention cysts. Salivary gland cystic abnormalities can be classified as either true cysts (e.g., lymphoepithelial cysts) or non-developmental cysts (e.g., retention cysts)^{7,8}.

Fine Needle Aspiration Cytology (FNAC) has proven to be an efficient, simple, and safe method for evaluating salivary gland enlargement. FNAC boasts high sensitivity, specificity, and accuracy in identifying salivary gland lesions^{1,2}. The sensitivity of FNAC for salivary gland lesions ranges from 86% to 100%, while specificity ranges from 90% to 100%⁸. The accuracy of FNAC is highly dependent on the experience of both the pathologist and the clinician performing the aspiration¹. FNAC is crucial in treatment planning, as it allows clinicians to avoid unnecessary surgeries and reduces healthcare costs⁹. While open biopsy may provide diagnostic information, it is generally avoided due to its invasiveness, which can complicate subsequent surgical interventions¹⁰.

1.2. Statement of the problem

Salivary gland swellings represent a diverse and challenging group of disorders with variable clinical presentations, making accurate diagnosis essential¹. While Fine-Needle Aspiration Cytology (FNAC) is widely used for the preoperative evaluation of head and neck tumors, its accuracy in diagnosing salivary gland masses remains debated in comparison to other diagnostic modalities. FNAC is a commonly performed, safe, and typically well-tolerated procedure that provides valuable diagnostic information. The primary goal of FNAC in salivary gland swelling is to distinguish between inflammatory and reactive processes, identify benign versus malignant neoplasms, and provide a definitive diagnosis when possible.

The accuracy of FNAC significantly impacts the surgical management of salivary gland swellings. It has been suggested that preoperative FNAC results play a key role in determining the management strategy for salivary gland swellings, including the decision to proceed with surgery. Knowing whether a lesion is malignant or benign in advance can help clinicians tailor surgical approaches, which could potentially delay or expedite intervention. Despite the unknown prevalence of salivary gland swellings in our region, many patients with these swellings present to our institution for diagnosis and management. Given the limited access to advanced imaging modalities such as CT or MRI, clinicians rely heavily on FNAC and clinical examination to guide their decisions. This study aims to correlate FNAC diagnoses with histopathology and assess the sensitivity and specificity of FNAC in diagnosing salivary gland swellings in our institution.

1.3. General objective

The general objective of this study is to compare the FNAC results with histopathology findings of salivary gland swellings in order to assess its diagnostic accuracy among patients who had both FNAC and histopathology results at Saint Paul's Hospital Millennium Medical College, Department of ORL HNS, and the Oral and Maxillofacial Surgery Department in Addis Ababa, Ethiopia, from January 1, 2019, to August 30, 2022, G.C.

1.4. Specific objectives

The specific objectives of this study are as follows:

- To determine the accuracy of FNAC diagnosis of salivary gland swelling when compared with histopathology.
- To evaluate the sensitivity and specificity of FNAC in diagnosing salivary gland swellings in our institution.
- To identify the patterns of etiology of salivary gland swellings in our institution.

1.5. Significance of the study

The surgical management of salivary gland swellings is increasingly dependent on preoperative FNAC results. This study aims to evaluate the sensitivity, specificity, positive predictive value, negative predictive value, and accuracy of FNAC in diagnosing salivary gland swellings in our institution. These diagnostic metrics will help guide surgeons in determining how much reliance should be placed on FNAC findings in their preoperative decision-making process. By improving the accuracy of preoperative diagnoses, this study may contribute to more informed surgical decisions, optimizing patient outcomes, and potentially reducing unnecessary surgeries.

2. Methods

2.1. Study setting and period

The study was conducted at Saint Paul's Hospital Millennium Medical College in Addis Ababa, Ethiopia, over the period from January 1, 2019, to August 30, 2022, G.C. Data collection took place from September 1-8, 2022, G.C.

2.2. Study design

This was a hospital-based cross-sectional study conducted on patients admitted to Saint Paul's Hospital Millennium Medical College, within the Department of ORL HNS and the Oral and Maxillofacial Surgery Department, who presented

with salivary gland swelling between January 1, 2019, and August 30, 2022, G.C. The study involved comparing FNAC results to histopathology reports for salivary gland swellings. We assessed the diagnostic accuracy of FNAC by calculating its sensitivity, specificity, positive predictive value (PPV), negative predictive value (NPV), and overall accuracy in comparison to histopathology results.

2.3. Study population

The source population included all patients with salivary gland swellings admitted to Saint Paul's Hospital Millennium Medical College, Department of ORL HNS, and the Oral and Maxillofacial Surgery Department from January 1, 2019, to August 30, 2022, G.C. The study population comprised patients who had both FNAC and histopathology results and were diagnosed with salivary gland tumors, cysts, or inflammation during the study period.

2.4. Eligibility criteria

2.4.1. Inclusion criteria: All patients with salivary gland swellings who had both FNAC and histopathology results during the study period.

2.4.2. Exclusion criteria: Patients without FNAC or histopathology results were excluded from the study. Patients with acute infections (viral or bacterial causes) were also excluded from the study.

2.5. Sample size determination

The sample size was calculated using a single population proportion formula, based on a 7% prevalence of salivary gland swellings from a prior study conducted at Addis Ababa University. The formula used was:

$$n = \frac{z^2 p(1 - p)}{e^2}$$

n = the required sample size

p = proportion of patients who have salivary gland swelling.

$Z_{\alpha/2}$ = the critical value at 95% confidence level = 1.96

e = precision (margin of error) = 5%

Accordingly,

$$n = \frac{(1.96)^2 * 0.07(1 - .07)}{0.05^2}$$

$$n = \frac{(1.96)^2 * 0.07(.93)}{0.05^2}$$

$$n = 100$$

Adding a non-response rate of 10% the final sample size will be 110.

2.6. Sampling procedure

A non-probability convenience sampling method was used to select patients from the study population.

2.7. Study variables

2.7.1. Dependent variables:

- **Benign salivary tumors:** Pleomorphic adenoma, Warthin's tumor, Basal cell adenoma, Myoepithelioma, Hemangioma, Lymphoepithelial lesions.

- **Malignant salivary tumors:** Mucoepidermoid carcinoma, Adenoid cystic carcinoma, Adenocarcinoma, Ex-pleomorphic carcinoma, Acinar cell carcinoma, Myoepithelial carcinoma, Basal cell carcinoma, Papillary cystadenocarcinoma.
- **Non-neoplastic salivary tumors:** Chronic sialadenitis, Vascular lesion, Unspecified cyst, Mucocele.

2.7.2. Independent variables:

- **Sociodemographic variables:** Age, sex, side of swelling (left, right, bilateral), duration of swelling, and affected gland (parotid, submandibular, sublingual, minor salivary gland).

2.8. Operational definitions

- **Fine Needle Aspiration Cytology (FNAC):** A diagnostic procedure where a thin needle is inserted into a salivary gland mass to aspirate cells, which are then examined microscopically.
- **Histopathology:** The study of tissues for diagnosing diseases, involving microscopic examination of tissue biopsies, which serves as the gold standard diagnostic method.
- **Benign tumors:** Tumors that resemble the tissue of origin, lack invasion, and exhibit mild growth with normal mitotic figures.
- **Malignant tumors:** Tumors that are poorly differentiated, show a high mitotic rate, and have invasive and metastatic potential.
- **Chronic sialadenitis:** Chronic inflammation of the salivary glands characterized by macrophages, monocytes, lymphocytes, and proliferating blood vessels and connective tissue.
- **Mucocele:** A cystic swelling caused by disruption of normal salivary secretion flow.

2.9. Data collection procedures and tools

The data were collected through a review of patient medical records, using well-standardized and pre-tested questionnaires. The data collection was conducted by trained ORL HNS residents.

2.9.1. Data quality assurance: To ensure the accuracy of the data, a well-trained data collector and supervisor were assigned to monitor data collection. All collected data were reviewed and checked daily for completeness.

2.10. Data analysis procedure

The collected data were verified for completeness before entering the analysis phase. Incomplete or erroneous data were cleaned and removed. The final dataset was entered into SPSS version 27 for analysis. Descriptive statistics, including tables, charts, and graphs, were used to present the socio-demographic characteristics of the study population. The diagnostic accuracy of FNAC was assessed by calculating its sensitivity, specificity, positive predictive value, negative predictive value, and overall accuracy in comparison to histopathology.

2.11. Dissemination of results

Upon completion of the study, the results will be submitted to the relevant departments at Saint Paul's Hospital Millennium Medical College, including the ORL HNS, Oral and Maxillofacial Surgery, and Pathology Departments. Additionally, the findings will be prepared for publication in peer-reviewed scientific

journals and presented at relevant scientific conferences to ensure broader dissemination of the results.

3. Results

3.1. Socio-demographic characteristics of study participants

A total of 110 patients were included in the study, with 60 females (54.5%) and 50 males (45.5%). The female-to-male ratio was approximately 1.2:1. The mean age of the participants was 37.5 ± 16.9 years, with an age range of 12 to 79 years (Table 1).

Table 1: Socio-demographic characteristics of patients with salivary gland swelling and operated at SPHMMC, Addis Ababa Ethiopia, 2022.

Variables	Frequency (%)
Age Group	
20-Nov	16(14.5)
21-29	24(21.8)
31-39	24(21.8)
41-49	18(16.4)
51-59	17(15.5)
61-69	8(7.3)
71-79	3(2.7)
Gender	
Male	50(45.5)
Female	60(54.5)

The average duration of salivary gland swelling was 2.95 years, with a minimum duration of 5 months and a maximum of 15 years. Regarding the laterality of the swelling, 60 (54.5%) of the cases presented with left-sided swelling, while 50 (45.5%) presented with right-sided swelling.

Regarding the distribution of salivary gland swellings, the parotid gland was most frequently involved (46.4%), followed by the submandibular gland (42.7%), minor salivary glands (10.9%), and the sublingual gland (0%) (Table 2, Figure 1).

Table 2: Site of salivary gland swelling with histopathology results at SPHMMC, Addis Ababa Ethiopia, 2022.

Site of swelling	Frequency (%)
Minor salivary gland	12(10.9)
Parotid	51(46.4)
Submandibular	47(42.7)
Total	110

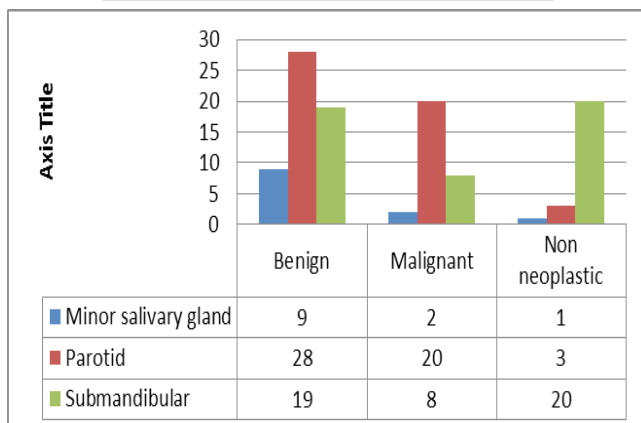


Figure 1: Site of salivary gland swelling with histopathology results at SPHMMC, Addis Ababa Ethiopia, 2022.

Among the parotid gland swellings, 54.9% were benign lesions, with pleomorphic adenoma (43.1%) being the most prevalent benign lesion. Non-neoplastic lesions, primarily chronic sialadenitis, accounted for 46.8% of submandibular swellings. Mucoepidermoid carcinoma was the most frequent malignant histopathological finding in the parotid, submandibular, and minor salivary glands (Figures 2,3 and 4).

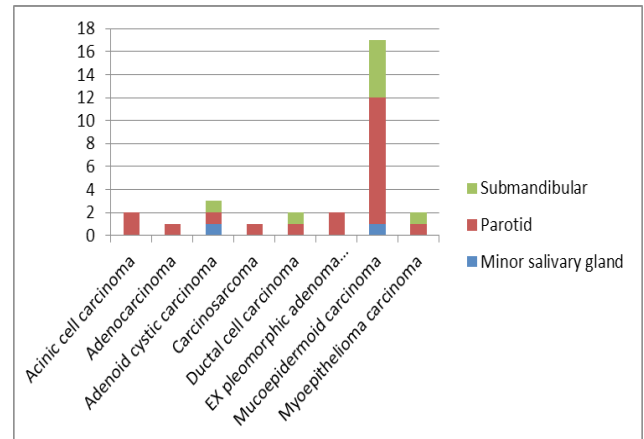


Figure 2: Site of salivary gland swelling with histopathology malignant result at SPHMMC, Addis Ababa Ethiopia, 2022.

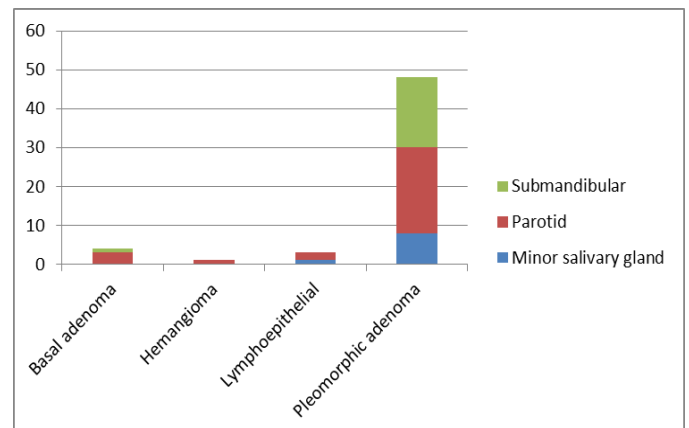


Figure 3: Site of salivary gland swelling with histopathology benign result at SPHMMC, Addis Ababa Ethiopia, 2022.

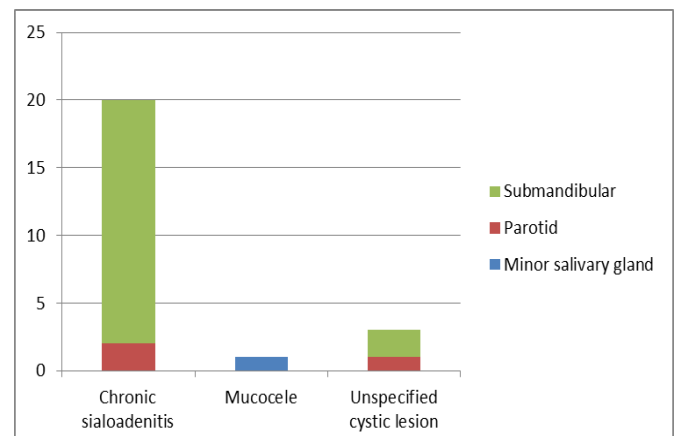


Figure 4: Site of salivary gland swelling with histopathology non neoplastic result at SPHMMC, Addis Ababa Ethiopia, 2022.

3.2. FNAC results

FNAC results revealed that 27 cases (24.5%) were diagnosed as malignant, 58 cases (52.7%) as benign tumors, and 25 cases (22.7%) as non-neoplastic lesions. Pleomorphic adenoma was the most common benign tumor, accounting for 52 cases

(89.65%), followed by lymphoepithelial lesions (3 cases, 5.1%), basal adenoma (2 cases, 3.4%), and hemangioma (1 case, 1.7%).

Among the malignant tumors diagnosed by FNAC, mucoepidermoid carcinoma was the most frequently observed, accounting for 14 cases (51.85%). Other malignant tumors included adenoid cystic carcinoma (4 cases, 14.81%), undifferentiated carcinoma (2 cases, 7.4%), ex-pleomorphic adenocarcinoma (2 cases, 7.4%), acinic cell carcinoma (2 cases, 7.4%), carcinosarcoma (1 case, 3.7%), ductal carcinoma (1 case, 3.7%), and adenocarcinoma (1 case, 3.7%).

Among the non-neoplastic lesions, chronic sialadenitis was the most common (21 cases, 84%), followed by unspecified cyst lesions (3 cases, 12%) and mucocoele (1 case, 4%) (Table 3).

Table 3: FNAC result and its cytology subtype of lesion of salivary gland swelling at SPHMMC, Addis Ababa Ethiopia, 2022.

Variables	Frequency(%)
FNAC result	
Benign	58(52.7)
Malignant	27(24.5)
Non neoplastic	25(22.7)
Total	110
Sub type of Benign lesion	
Basal adenoma	2(34.4)
Hemangioma	1(1.72)
Lymphoepithelial lesion	3(5.1)
Pleomorphic adenoma	52(89.65)
Total	58
Sub type of Malignant lesion	
Acinic cell carcinoma	2(7.4)
Adenocarcinoma	1(3.7)
Adenoid cystic carcinoma	4(14.8)
Carcinosarcoma	1(3.7)
Ductal carcinoma	1(3.7)
Ex pleomorphic adenoma	2(7.4)
Mucoepidermoid carcinoma	14(51.85)
Undifferentiated carcinoma	2(7.4)
Total	27
Non neoplastic sub type	
Chronic sialadenitis	21(84)
Mucocoele	1(4)
Unspecified cystic lesion	3(12)
Total	25

3.3. Histopathology results

The final histopathologic diagnosis revealed 30 malignant tumors (27.3%), 56 benign tumors (50.9%), and 24 non-neoplastic lesions (21.8%).

The most common malignant tumor was mucoepidermoid carcinoma, observed in 17 cases (56.66%), followed by adenoid cystic carcinoma (3 cases, 10%), ductal carcinoma (2 cases, 6.66%), acinic cell carcinoma (2 cases, 6.66%), ex-pleomorphic adenocarcinoma (2 cases, 6.66%), myoepithelial carcinoma (2 cases, 6.66%), adenocarcinoma (1 case, 3.33%), and carcinosarcoma (1 case, 3.33%).

Among the benign lesions, pleomorphic adenoma was the most prevalent, seen in 48 cases (85.7%), followed by basal

adenoma (4 cases, 7.1%), lymphoepithelial lesions (3 cases, 5.3%), and hemangioma (1 case, 1.7%).

Chronic sialadenitis was the most common non-neoplastic lesion, accounting for 20 cases (83.3%), followed by unspecified cyst lesions (3 cases, 8.33%) and mucocoele (1 case, 4.16%) (Table 4).

Table 4: Histopathology result and its subtype of lesion of salivary gland swelling and operated at SPHMMC, Addis Ababa Ethiopia, 2022.

Variables	Frequency(%)
Histopathology result	
Benign	56(50.9)
Malignant	30(27.3)
Non neoplastic	24(21.8)
Total	110
Malignant subtype	
Acinic cell carcinoma	2(6.66)
Adenocarcinoma	1(3.33)
Adenoid cystic carcinoma	3(10)
Carcinosarcoma	1(3.33)
Ductal carcinoma	2(6.66)
Ex pleomorphic adenoma	2(6.66)
Mucoepidermoid carcinoma	17(56.66)
Undifferentiated carcinoma	2(6.66)
Total	30
Benign subtype	
Basal adenoma	4(7.1)
Hemangioma	1(1.7)
Lymphoepithelial lesion	3(5.3)
Pleomorphic adenoma	48(85.7)
Total	56
Non neoplastic subtype	
Chronic sialadenitis	20(83.33)
Mucocoele	1(4.16)
Unspecified cystic lesion	3(12.5)
Total	24

3.4. Discordant results between FNAC and histopathology

Discordant results were observed in 16 cases, where the FNAC diagnosis did not match the histopathology findings. Specific discordances included:

- One case of carcinoma ex-pleomorphic adenoma, which was diagnosed as pleomorphic adenoma by FNAC.
- Three cases diagnosed as mucoepidermoid carcinoma on histopathology were diagnosed as pleomorphic adenoma by FNAC.
- One case of acinic cell carcinoma was misdiagnosed as ductal cell carcinoma by FNAC.
- Two cases of ductal cell carcinoma were diagnosed as undifferentiated carcinoma and acinic cell carcinoma by FNAC.
- Two cases of myoepithelial carcinoma were diagnosed as mucoepidermoid carcinoma and adenoid cystic carcinoma by FNAC.
- Two cases of basal adenoma were diagnosed as pleomorphic adenoma by FNAC.

- Two cases of pleomorphic adenomas were diagnosed as mucoepidermoid carcinoma by FNAC.
- Three cases of mucoepidermoid carcinoma were diagnosed as chronic sialadenitis, ex-pleomorphic adenoma, and undifferentiated carcinoma by FNAC (Table 5).

Table 5: Cases with discordant in cyto histopathological diagnosis, SPHMMC, Addis Ababa, Ethiopia, 2022.

Cytology diagnosis	Histopathology diagnosis
Pleomorphic adenoma	Basal adenoma
Pleomorphic adenoma	Basal adenoma
Pleomorphic adenoma	Mucoepidermoid carcinoma
Pleomorphic adenoma	Mucoepidermoid carcinoma
Pleomorphic adenoma	Mucoepidermoid carcinoma
Pleomorphic adenoma	Ex pleomorphic adenoma
Chronic sialadenitis	Mucoepidermoid carcinoma
Ductal carcinoma	Acinic cell carcinoma
Ex pleomorphic adenoma	Mucoepidermoid carcinoma
Mucoepidermoid carcinoma	Myoepithelial carcinoma
Acinic cell carcinoma	Ductal carcinoma
Mucoepidermoid carcinoma	Pleomorphic adenoma
Mucoepidermoid carcinoma	Pleomorphic adenoma
Undifferentiated carcinoma	Ductal carcinoma
Undifferentiated carcinoma	Mucoepidermoid carcinoma
Acinic cell carcinoma	Myoepithelial carcinoma

3.5. Diagnostic accuracy assessment

The diagnostic accuracy of FNAC was evaluated by calculating its sensitivity, specificity, Positive Predictive Value (PPV), Negative Predictive Value (NPV), and overall accuracy for each category of salivary gland pathology.

Benign cases:

- Sensitivity: 96.42%
- Specificity: 92.6%
- Positive Predictive Value (PPV): 93.1%
- Negative Predictive Value (NPV): 96.1%
- Accuracy: 94.54%

Malignant cases:

- Sensitivity: 83.3%
- Specificity: 95.5%
- PPV: 92.6%
- NPV: 93.97%
- Accuracy: 93.63%

Non-neoplastic cases:

- Sensitivity: 100%
- Specificity: 98.83%
- PPV: 96%
- NPV: 100%
- Accuracy: 99.09%

4. Discussion

Fine Needle Aspiration Cytology (FNAC) is a widely used diagnostic technique for evaluating salivary gland enlargement, offering a simple, rapid, and safe procedure. FNAC is known

for its high sensitivity, specificity, and accuracy, with sensitivity ranging from 86% to 100% and specificity from 90% to 100% in diagnosing salivary gland lesions^{1,2,8}. The accuracy of FNAC is significantly influenced by the experience of both the pathologist and the clinician performing the aspiration¹. FNAC plays a crucial role in treatment planning, helping to avoid unnecessary surgeries and reducing hospital costs⁹.

Table 6: Cross tabs between FNAC and histopathology result of salivary gland swelling and operated at SPHMMC, Addis Ababa Ethiopia, 2022.

		Biopsy benign		
FNAC benign		No	Yes	Total
	No	50	2	52
	Yes	4	54	58
	Total	54	56	110
FNAC malignant		Biopsy malignant		
		No	Yes	Total
	No	78	5	83
	Yes	2	25	27
FNAC non-neoplastic		Biopsy non neoplastic		
		No	Yes	Total
	No	85	0	85
	Yes	1	24	25
FNAC non-neoplastic	Total	86	24	110

Table 7: Parameters of validity measurement for non-neoplastic, benign and malignant FNAC result of salivary gland swelling in comparison with histopathology result, SPHMMC, Addis Ababa, Ethiopia, 2022.

Parameters of validity	Value (%)		
	Non-neoplastic	Benign	Malignant
Sensitivity	100%	96.42%	83.30%
Specificity	98.83%	92.60%	95.50%
Positive predictive value	96%	93.10%	92.60%
Negative predictive value	100%	96.10%	93.97%
Accuracy	99.09%	94.51%	93.63%

In our study, patients ranged in age from 12 to 79 years, with a mean age of 37.5 years, and a male-to-female ratio of 1:1. Previous studies in Nepal reported a similar age range, with a median of 38 years⁷. Research from Liaquat National Hospital indicated an average age of 42 years (± 21), with a male-to-female ratio of 1:1, while another study reported a mean age of 35.7 years (± 19.3 years) and a male-to-female ratio of 1.2:1. Additionally, research in Tanzania indicated a peak age range between 20 and 49 years, with a male-to-female ratio of 1.5:1^{7,11-14}.

Regarding the distribution of salivary gland swellings, our study found that 46.4% of swellings were in the parotid gland, 42.7% in the submandibular gland, 10.9% in the minor salivary glands, and 0% in the sublingual gland. Other studies have reported comparable findings, with one study showing 68% parotid gland involvement, 30% submandibular, 2% minor salivary gland, and 0% sublingual involvement^{14,16}. Another study indicated 48.3% parotid, 41.2% submandibular, and 10.4% minor salivary gland involvement, again with no sublingual gland involvement.

In terms of the final pathological diagnosis, our study identified 30 malignant tumors (27.3%), 56 benign tumors (50.9%), and 24 non-neoplastic lesions (21.8%). A comparable study found that non-neoplastic lesions made up 53.22% (66/124) of all cases, followed by benign tumors (31.45%, 39/124) and malignant tumors (15.32%)¹⁶. Another study also found similar proportions, with 27.3% malignant tumors, 50.9% benign tumors, and 21.8% non-neoplastic lesions¹⁵.

The most frequent pathological findings in our study included pleomorphic adenoma (benign), mucoepidermoid carcinoma (malignant), and chronic sialadenitis (non-neoplastic). These findings are consistent with other studies, where chronic sialadenitis was the most common non-neoplastic lesion, pleomorphic adenoma was the most common benign lesion, and adenoid cystic carcinoma was the most frequent malignant lesion^{7,11,13,17-19}. In one study, non-Hodgkin lymphoma was the most prevalent malignant lesion, while pleomorphic adenoma was again the most common benign lesion. Another study found pleomorphic adenoma to be the most common tumor (44.4%), followed by adenoid cystic carcinoma (24.8%) and mucoepidermoid carcinoma (9.8%). Pleomorphic adenoma also emerged as the most common neoplasm (63%) in a separate investigation, with Warthin's tumor accounting for 17.5%.

The parotid gland was the most frequent site of swelling in our study, consistent with the findings from Addis Ababa University, where sialadenitis affected 29.8% of patients, with the submandibular gland being the most commonly affected site²⁰. In our study, pleomorphic adenoma was the most common lesion in the parotid and minor salivary glands, while chronic sialadenitis was most frequently found in the submandibular gland.

Our diagnostic performance analysis revealed that the sensitivity, specificity, and accuracy for non-neoplastic lesions were 100%, 98.83%, and 99.09%, respectively; for benign neoplasms, they were 96.42%, 92.6%, and 94.54%; and for malignant neoplasms, they were 83.3%, 95.5%, and 94.54% (Tables 5-7). In comparison, other studies have reported varying values. One study found the sensitivity, specificity, and accuracy to be 100%, 89.28%, and 91.67% for non-neoplastic lesions; 100%, 86.95%, and 91.67% for benign neoplasms; and 57.14%, 100%, and 83.33% for malignant neoplasms. Another study reported a 100% sensitivity, 95.8% specificity, and 93% accuracy for non-neoplastic lesions, with 98.78% accuracy for benign lesions and 77.77% for malignant lesions^{7,13,14,16}.

The Positive Predictive Values and Negative Predictive Values (PPV and NPV) in our study were 93.1% and 96.1% for benign lesions, 92.6% and 93.97% for malignant lesions, and 96% and 100% for non-neoplastic lesions. One study reported PPV and NPV for benign and malignant tumors as 94.36% and 96.55%, respectively, with 93.33% PPV and 95.29% NPV for malignant tumors. Another study found FNAC to have a 97% negative predictive value (NPV), with a PPV of 92.3% and NPV of 93.6%^{6,14,18}.

5. Strengths and Limitations

The main strength of this study is its contribution to understanding the diagnostic accuracy of FNAC for salivary gland swellings. Given that incisional biopsy is not recommended

for these conditions, FNAC plays a pivotal role in influencing the surgical approach, providing a reliable foundation for treatment planning. Our findings underscore the usefulness of FNAC in guiding surgical decisions, thereby reducing unnecessary procedures and minimizing hospital costs.

However, the study has some limitations:

- **Lack of immunohistochemistry:** We did not utilize Immunohistochemistry (IHC), which could have provided further insights into the various histologic categories and their precise classifications.
- **Retrospective data:** Since the study was based on retrospectively collected data, the validity measurements might be either overestimated or underestimated.
- **Reliability issues:** Due to the retrospective nature of the data, it is difficult to perform reliability testing and to fully assess the causes of false positive and false negative FNAC results.

6. Conclusion

FNAC is a highly sensitive and specific diagnostic tool for salivary gland swellings. It is particularly useful for distinguishing benign from malignant lesions and guiding surgical management.

7. Recommendations

- **For healthcare professionals:** FNAC should be routinely used for preoperative evaluation of salivary gland swellings to avoid unnecessary surgeries.
- **For policymakers:** Establish pathology laboratories in all healthcare institutions to improve access to FNAC services.
- **For researchers:** Conduct multicenter studies with larger sample sizes to further validate the diagnostic accuracy of FNAC.

8. Declarations

Ethical approval was obtained from the Ethical Review Board of Saint Paul's Hospital Millennium Medical College. Written consent was obtained from patients or their guardians before participation. The confidentiality of patient data was strictly maintained throughout the study. Consent for publication was obtained from the patient and is available upon request from the corresponding author.

9. Authors' Contributions

Mohammedsefa Arusi Dari and Dr. Zelalem Tadesse Wondimu

- Substantial contributions to conception and study design;
- drafting the article and the manuscript
- final approval of the version to be published.

Dr. Zeyneb Saleh

- acquisition of data, or analysis and interpretation of data;
- revising it critically for important intellectual content;
- final approval of the version to be published.

10. Acknowledgment

The authors thank St. Paul's Hospital Millennium Medical College for supporting this study.

11. References

- Singh A, Haritwal A, Murali BM. Correlation between cytology and histopathology of the salivary gland. *Australas Med J*. 2011;4: 66-71.
- Koirala S, Sayami G, Pant AD. Correlation of FNAC and histopathology in diagnosis of salivary gland lesions. *J Pathology of Nepal*. 2014;4: 654-657.
- To VSH, Chan JYW, Tsang RKY, Wei WI. Review of Salivary Gland Neoplasms. *ISRN Otolaryngol*. 2012;2012: 1-6.
- Licitra L, Grandi C, Prott FJ, et al. Major and minor salivary gland tumours. *Crit Rev Oncol Hematol*. 2003;45: 215-25.
- Sneige N, Batsakis JG, El-Naggar AK. Pathology consultation. *Ann Otol Rhinol Laryngol*. 1992;101: 877-880.
- Huq AHMZ, Asa A. A comparative study between fine needle aspiration cytology findings and histopathological report of major salivary gland neoplasm in a tertiary hospital of Bangladesh. *Bangladesh Med Res Counc Bull*. 2013;39: 1-6.
- Gupta R, Dewan D, Kumar D, Suri J. Fine-needle aspiration cytology (FNAC) of salivary gland lesions with histopathological correlation in a district hospital of Jammu region. *Indian J Pathol Oncol*. 2016;3(1): 32-36.
- Pantanowitz L, Thompson LDR, Rossi ED. Diagnostic approach to fine needle aspirations of cystic lesions of the salivary gland. *Head Neck Pathol*. 2018;12(4): 548-561.
- Das DK, Petkar MA, Al-Mane NM, Sheikh ZA, Mallik MK, Anim JT. Role of fine needle aspiration cytology in the diagnosis of swellings in the salivary gland regions: A study of 712 cases. *Med Princ Pract*. 2004;13: 95-106.
- Zurrida S, Alasio L, Tradafi N, Bartoli C, Chiesa F, Pilotti S. Fine-needle aspiration of parotid masses. *Ann Surg Oncol*. 2010;17: 301-306.
- Masanja MI, Kalyanyama BM, Simon EN. Salivary gland tumors in Tanzania. *East Afr Med J*. 2003;80: 429-433.
- Aidya S. Correlation of FNAC and histopathology in salivary gland lesions. *J Pathology of Nepal*. 2011;1.
- Naz S, Hashmi AA, Khurshid A, et al. Diagnostic role of fine needle aspiration cytology (FNAC) in the evaluation of salivary gland swelling: An institutional experience. *BMC Res Notes*. 2015;8: 1-7.
- Ashraf A, Shaikh AS, Kamal F, Sarfraz R, Bukhari MH. Diagnostic reliability of FNAC for salivary gland swellings: A comparative study. *Diagn Cytopathol*. 2010;38: 499-504.
- Nazir RT, Sharif MA, Iqbal M, Amin MS. Diagnostic accuracy of fine needle aspiration cytology in hepatic tumors. *J Coll Physicians Surg Pakistan*. 2010;20: 373-376.
- Omhare A, Singh SK, Nigam JS, Sharma A. Cytohistopathological study of salivary gland lesions in Bundelkhand Region, Uttar Pradesh, India. *Pathol Res Int*. 2014;2014: 1-7.
- Liu CC, Jethwa AR, Khariwala SS, Johnson J, Shin JJ. Sensitivity, specificity, and posttest probability of parotid fine-needle aspiration: A systematic review and meta-analysis. *Otolaryngol Head Neck Surg*. 2016;154: 9-23.
- Gudmundsson JK, Ajan A, Abtahi J. The accuracy of fine-needle aspiration cytology for diagnosis of parotid gland masses: A clinicopathological study of 114 patients. *J Appl Oral Sci*. 2016;24: 561-567.
- Poudel A, Shrestha B, Regmi S. Evaluation of salivary gland lesions by fine needle aspiration cytology at a tertiary care hospital, Western Nepal. *Pathol Lab Med Int*. 2020;12: 9-17.
- Beyene M. Prevalence and patterns of salivary gland disease in maxillofacial surgery, affiliated hospital, Addis Ababa, Ethiopia. Addis Ababa University. 2022.

Annex I

- Data Collection Format
- St. Paul's Hospital Millennium Medical College
- The Purpose of this study is to compare and assess sensitivity and specificity of FNAC and histopathology reports of salivary gland swellings at Saint Paul's Hospital Millennium Medical College.
- I kindly request your willingness to perform these reviews. The information gathered will be used confidentially.

Code	Question	Response	Remark
Part one: Socio-demographic factors			
SD1	MRN (code)	_____	
SD2	Age	_____	
SD3	Sex	Male	
		Female	
Part two: Clinical characteristics			
CC1	Site of swollen gland	Parotid	
		submandibular	
		sublingual	
		Minor salivary gland	
CC2	Side of swelling	Right	
		Left	
CC3	Duration of swelling		
Part three: Cytopathology pathology (FNAC) findings			

CP1	FNAC	Benign	
		Malignant	
		Non neoplastic	
CP2	Benign subtypes	Pleomorphic adenoma	
		Warthin tumor	
		Basal cell adenoma	
		adenoma	
		hemangioma	
CP3	Malignant subtypes	Mucoepidermoid carcinoma	
		Adenoid cystic carcinoma	
		Squamous cell carcinoma	
		Ex pleomorphic carcinoma	
		adenocarcinoma	
		Basal cell carcinoma	
		Acinar cell carcinoma	
		Ductal carcinoma	
CP4	Non neoplastic	mucocoele	
		Chronic sialadenitis	
		Congenital vascular anomalies	
		Cystic lesion	
Part four: Histopathology findings			
HP1	Histopathology result	benign	
		malignant	
		Non neoplastic	
HP2	Benign	Pleomorphic adenoma	
		Warthin tumor	
		Basal cell adenoma	
		Adenoma	
		hemangioma	
HP3	Malignant subtypes	Mucoepidermoid carcinoma	
		Adenoid cystic carcinoma	
		Squamous cell carcinoma	
		Ex pleomorphic carcinoma	
		adenocarcinoma	
		Basal cell carcinoma	
		Acinar cell carcinoma	
		Ductal carcinoma	
HP4	Non neoplastic	mucocoele	
		Chronic sialadenitis	
		Congenital vascular anomalies	
		Cystic lesion	