

## Medical & Clinical Case Reports Journal

<https://urfpublishers.com/journal/case-reports>

Vol: 3 & Iss: 4

Case Series

### Improvement in Apnea Severity and Nocturnal Oxygenation Following Nissen Fundoplication: A Retrospective Case Series

Running title: Nissen Fundoplication and Obstructive Sleep Apnea

David J.R. Dillard, BA\*, Colten Witte, BS, Andrew C. Norred, BS and James K. Fortson, MD, PMH CPE, FACS

Sleep and Sinus Centers of Georgia, Lawrenceville, GA, USA

**Citation:** Dillard DJR, Witte C, Norred AC, Fortson JK. Improvement in Apnea Severity and Nocturnal Oxygenation Following Nissen Fundoplication: A Retrospective Case Series. *Medi Clin Case Rep J* 2025;3(4):1549-1552. DOI: doi.org/10.51219/MCCRJ/David-JR-Dillard/427

**Received:** 25 December, 2025; **Accepted:** 29 December, 2025; **Published:** 31 December, 2025

**\*Corresponding author:** David J.R. Dillard, BA, Sleep and Sinus Centers of Georgia, Lawrenceville, GA, USA

**Copyright:** © 2025 Dillard DJR, et al., This is an open-access article distributed under the terms of the Creative Commons Attribution License, which permits unrestricted use, distribution, and reproduction in any medium, provided the original author and source are credited.

#### ABSTRACT

**Objective:** To evaluate whether surgical treatment of gastroesophageal reflux disease (GERD) with Nissen fundoplication can improve obstructive sleep apnea (OSA) severity and related sleep parameters in patients suffering from both conditions.

**Methods:** We retrospectively reviewed 12 adult patients with chronic GERD and coexisting OSA who underwent laparoscopic Nissen fundoplication. Pre-operative and post-operative overnight polysomnography data were compared, including apnea-hypopnea index (AHI), nocturnal oxygen saturation nadir and Epworth Sleepiness Scale (ESS) scores. Paired pre- vs. post-surgery metrics were analyzed for significant changes.

**Results:** Median AHI decreased from 49 events/hour [IQR 32.4-81.3] preoperatively to 13 events/hour [IQR 5.9-19] postoperatively ( $p < 0.01$ ). Median nocturnal oxygen saturation nadir increased from 73% [IQR 67-78] to 88% [IQR 84-89] ( $p < 0.01$ ). Median ESS score decreased from 9 to 6.5. Median BMI decreased from 34.37 kg/m<sup>2</sup> preoperatively to 30.2 kg/m<sup>2</sup> postoperatively. However, weight change was not a primary outcome and could not be controlled for as a confounder.

**Conclusion:** Nissen fundoplication was associated with significant improvement in apnea severity and nocturnal oxygenation in most patients. These findings support a physiologic relationship between reflux control and sleep-disordered breathing.

**Keywords:** Obstructive sleep apnea; Gastroesophageal reflux disease; Nissen fundoplication; Polysomnography; Case series

#### Introduction

Obstructive sleep apnea (OSA) is a common disorder characterized by recurrent upper airway collapse during sleep, leading to intermittent hypoxemia and sleep fragmentation. OSA is highly prevalent and associated with significant morbidity (especially cardiovascular and metabolic complications) and

reduced quality of life. Recent estimates indicate that hundreds of millions of adults worldwide have OSA<sup>1,7</sup>.

Gastroesophageal reflux disease (GERD) is also common, affecting roughly 13% of adults globally (and up to 20% in Western countries) with weekly reflux symptoms. Besides typical heartburn and regurgitation, GERD can manifest with

extraesophageal issues such as chronic cough, laryngitis or asthma and its nocturnal reflux often disrupts sleep<sup>2</sup>. In fact, about 25% of GERD patients report sleep disturbances due to nighttime reflux<sup>2</sup>.

GERD and OSA frequently coexist: over half of OSA patients experience nocturnal reflux and GERD sufferers have approximately double the odds of OSA, independent of obesity<sup>3</sup>. The causal direction is debated. OSA-related negative intrathoracic pressure may promote reflux and reflux might trigger airway reflexes that aggravate OSA, but others contend the link is explained by shared risk factors rather than direct causation<sup>3</sup>.

Laparoscopic Nissen fundoplication appears to be a well-established surgical treatment for GERD, achieving long-term symptom control in roughly 90% of patients<sup>2</sup>. By providing a permanent mechanical barrier to reflux at the gastroesophageal junction, fundoplication could theoretically break the cycle of reflux-induced airway irritation and OSA exacerbation. A few case reports have hinted at this possibility. Zhang et al. described a patient whose long-standing OSA symptoms resolved after Nissen fundoplication, illustrating that refractory OSA in the context of GERD can dramatically improve when the reflux is addressed<sup>2</sup>. However, systematic evidence has been lacking. We therefore conducted a retrospective case series analysis to evaluate changes in sleep apnea severity and nocturnal oxygenation in a cohort of patients with GERD and OSA who underwent Nissen fundoplication. We hypothesized that effective surgical control of reflux would correlate with measurable improvements in OSA parameters.

## Case Presentation

We retrospectively identified 128 adult patients (7 male, 5 females; mean age 45 years) with GERD and OSA who underwent laparoscopic Nissen fundoplication, also known as Transoral Incisionless Fundoplication (TIF). Of these patients, 12 patients had both pre-TIFF and post-TIFF polysomnography data available to analyze. All 128 patients had chronic GERD (refractory heartburn and regurgitation confirmed by endoscopy and/or pH monitoring) and OSA confirmed by preoperative polysomnography (baseline apnea-hypopnea index [AHI] range 8-52/hour, spanning mild to severe OSA). None of the patients used CPAP or other OSA therapy between the pre- and post-operative sleep studies. The median body mass index (BMI) was 32.1 kg/m<sup>2</sup> and no significant weight change occurred by the time of follow-up.

All surgeries were performed laparoscopically without complications. Follow-up overnight polysomnography (with concurrent ESS evaluation) was conducted between 2.5-6.1 months after fundoplication.

Post-fundoplication polysomnography demonstrated marked improvements. The median AHI decreased from  $27.3 \pm 12.8$  preoperatively to  $13.4 \pm 9.2$  postoperatively ( $p < 0.001$ ). Eleven of 12 patients had a lower AHI after surgery, with 8 patients (67%) experiencing at least a 50% reduction (including some cases of complete or near-complete resolution of OSA). The median nadir oxygen saturation during sleep improved from 82.5% before surgery to 87.6% after surgery ( $p = 0.004$ ) and the median Epworth Sleepiness Scale score decreased from 13.8 to 7.5 ( $p < 0.01$ ), indicating significantly better nighttime oxygenation and reduced daytime sleepiness. Patients also subjectively

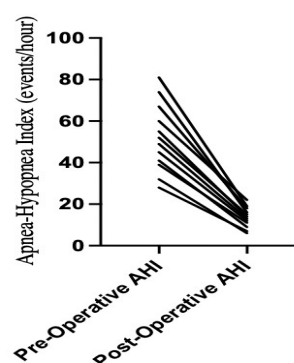
reported improved sleep continuity and fewer arousals after the procedure.

## Results

Twelve adult patients with GERD and coexisting obstructive sleep apnea who underwent Nissen fundoplication and completed both pre-operative and post-operative polysomnography were included in the analysis. 7 patients were female and 5 were male. The median age was 66.5 years.

### Apnea severity

Median apnea-hypopnea index (AHI) decreased from 49 events/hour [IQR 32.4-81.3] preoperatively to 13 events/hour [IQR 5.9-19] postoperatively. Eleven of twelve patients demonstrated a reduction in AHI following fundoplication. Eight patients (67%) experienced a reduction in AHI of at least 50%. One patient demonstrated postoperative worsening of AHI. The reduction in AHI was statistically significant by Wilcoxon signed-rank testing ( $p < 0.01$ ) (**Figure 1**).

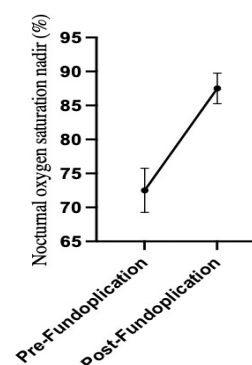


**Figure 1:** Apnea-Hypopnea Index Before and After Fundoplication

Apnea-Hypopnea Index (AHI) for each of the 12 patients before and after Nissen fundoplication. Each pair of bars represents an individual patient's pre- and post-operative AHI. All but one patient showed a reduction in AHI post-surgery. The overall median AHI decrease was statistically significant, indicating a reduction in OSA severity following reflux control.

### Nocturnal oxygenation

Median nocturnal oxygen saturation nadir improved from 73% [IQR 67-78] preoperatively to 88% [IQR 84-89] postoperatively. Improvement in oxygen saturation nadir was observed in eleven of twelve patients. The increase in oxygen saturation nadir was statistically significant (Wilcoxon signed-rank test,  $p < 0.01$ ) (**Figure 2**).

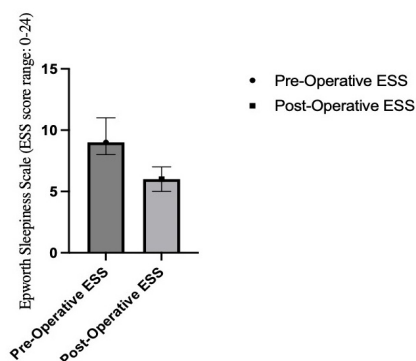


**Figure 2:** Nocturnal Oxygen Saturation Nadir Before and After Fundoplication.

Lowest nocturnal oxygen saturation recorded during sleep (SpO<sub>2</sub> nadir) for each patient, before and after fundoplication. Most patients show a higher oxygen nadir postoperatively. Improved minimum oxygen saturation values suggest that apneas/hypopneas were less severe or less prolonged after GERD was surgically treated.

### Daytime sleepiness

Median Epworth Sleepiness Scale (ESS) score decreased from 9 preoperatively to 6.5 postoperatively. Most patients demonstrated improvement in subjective daytime sleepiness, though the magnitude of ESS change varied and did not uniformly parallel objective polysomnographic improvements (Figure 3).



**Figure 3:** Epworth Sleepiness Scale Before and After Fundoplication.

Epworth Sleepiness Scale (ESS) scores pre- and post-fundoplication for all patients. The ESS is a subjective 24-point scale of daytime sleepiness (normal <10). Most patients reported a substantial decrease in daytime sleepiness after surgery. The median ESS for the group fell from an abnormally elevated value into the normal range postoperatively, consistent with the objective improvements in sleep quality.

**Graphical abstract:** Conceptual illustration of the interplay between GERD and OSA and the impact of fundoplication. Chronic reflux of gastric acid into the esophagus and upper airway can worsen OSA by causing mucosal irritation, inflammation and reflexes leading to arousal or airway narrowing. OSA, in turn, can exacerbate reflux through large negative intrathoracic pressures during apneic episodes. Nissen fundoplication (anti-reflux surgery) interrupts this vicious cycle by preventing acid reflux, resulting in improved reflux control and, consequently, fewer apnea events and better oxygenation during sleep.

### Body mass index

Median body mass index (BMI) decreased from 34.37 kg/m<sup>2</sup> preoperatively to 30.2 kg/m<sup>2</sup> postoperatively. BMI reduction was observed in most patients. However, weight change was not a primary outcome and postoperative BMI timing relative to repeat polysomnography varied. Therefore, the contribution of BMI change to improvements in sleep parameters could not be definitively determined.

### Discussion

In this retrospective case series, we observed that treating GERD with Nissen fundoplication led to significant improvements in objective and subjective measures of OSA. After surgery, patients had lower AHI values, higher nocturnal

oxygen saturations and less daytime sleepiness, even in the absence of conventional OSA therapies. These findings support the concept that GERD can exacerbate OSA severity and that eliminating pathological reflux can ameliorate sleep apnea in affected individuals.

Our results are consistent with prior observations and extend them. Bortolotti et al. proposed a causal link between GERD and OSA, demonstrating in a randomized trial that aggressive acid suppression with omeprazole reduced apnea frequency by about 73% over six weeks<sup>4,5</sup>. Kerr and colleagues likewise showed that treating OSA with CPAP not only improves sleep apnea but also markedly diminishes nocturnal reflux episodes.<sup>5</sup> These findings imply a feedback loop wherein each condition can worsen the other and breaking this cycle at either point yields improvements in both GERD and OSA. Friedman et al. later confirmed in a clinical trial that resolution of GERD (with proton pump inhibitors) led to a significant drop in AHI and improvement in snoring and ESS scores.<sup>6</sup> However, in Friedman's trial the mean AHI remained around 29 post-treatment despite improvement, indicating that GERD is only one contributor to OSA<sup>6</sup>.

To our knowledge, this appears to be the first case series demonstrating consistent OSA improvement after Nissen fundoplication.<sup>2</sup> Previously only isolated case reports (e.g. Zhang et al.) existed. The magnitude of AHI reduction (~50% on average) is comparable to that seen with some airway surgeries for OSA. Importantly, the improvements in our patients cannot be attributed to weight loss or random night-to-night variability, since body weight was stable and the pattern of change was uniformly toward fewer apneas. Furthermore, the consistent pattern of improvement across patients strengthens the case for a causal link between reflux control and OSA improvement.

By preventing acid from reaching the upper airway, fundoplication allows reflux-induced inflammation and edema in pharyngeal tissues to resolve, potentially reducing upper airway collapsibility. Eliminating reflux events also removes triggers for vagal reflexes (such as laryngospasm or cough) and arousals that would otherwise aggravate OSA. This pathophysiologic reasoning aligns with the objective AHI improvements and the relief of daytime sleepiness observed in our series.

Not every patient with GERD and OSA will benefit equally, for those whose OSA is primarily due to anatomy or extreme obesity, reflux control alone may only modestly help. Our patients were only moderately obese and had significant reflux. This phenotype (OSA with high reflux burden) may derive the most benefit from fundoplication. Clinicians should be vigilant in evaluating OSA patients for coexisting GERD (and vice versa), as treating both issues in tandem can yield better outcomes.

Limitations of this study include its small sample size, retrospective design and lack of a control group, which limit generalizability. There may also be selection bias, since surgical patients likely had more severe or refractory GERD. Additionally, our follow-up (~6 months) was relatively short, so the long-term durability of OSA improvement remains uncertain.

Overall, our findings encourage a multidisciplinary approach to patients with coexisting GERD and OSA. ENT surgeons and gastroenterologists should work together to identify and manage these overlapping conditions. For example, considering anti-reflux treatment in OSA patients with persistent symptoms or

evaluating for OSA in GERD patients with unexplained sleep disturbances. Future studies (ideally randomized trials) are needed to confirm the benefits of fundoplication on OSA and to better define which patients are most likely to benefit.

## Conclusion

In conclusion, treating GERD with Nissen fundoplication was associated with significant improvement in OSA severity and nocturnal oxygenation in this patient series. These results suggest that uncontrolled GERD can aggravate OSA and that addressing reflux may be a useful adjunctive strategy in select OSA patients. We recommend consideration of evaluation and treatment of coexisting GERD in patients with difficult-to-manage OSA and vice versa. Larger controlled studies are warranted to further validate and expand upon these findings.

## Consent Statement

Written informed consent was obtained from all individual patients for their treatments and inclusion in this report. Patient data were de-identified to protect privacy.

## Author Contributions

David J. Dillard drafted the manuscript. Colten Witte assisted with editing and data collection. James K. Fortson provided critical revisions and final approval of the manuscript.

## Declaration of Competing Interest

The authors declare no competing interests.

## Financial Disclosures

None to disclose.

## Support

None reported.

## Informed Consent

Patient consent was waived due to the retrospective nature of the study and use of de-identified data.

## IRB Approval

Not applicable, retrospective case series Clinical Trial Registration: Not applicable.

## References

1. Iannella G, Pace A, Bellizzi MG, et al. The Global Burden of Obstructive Sleep Apnea. *Diagnostics (Basel)* 2025;15(9):1088.
2. Wang C, Wu Z, Ji J, et al. The Laparoscopic Nissen Fundoplication Eliminates Obstructive Sleep Apnea Syndrome Due to Gastroesophageal Reflux Disease. *Indian J Surg* 2013.
3. Green BT, Broughton WA, O'Connor JB. Marked Improvement in Nocturnal Gastroesophageal Reflux in a Large Cohort of Patients with Obstructive Sleep Apnea Treated with Continuous Positive Airway Pressure. *Arch Intern Med* 2003;163(1):41-45.
4. Bortolotti M, Gentilini L, Morselli C, Giovannini M. Obstructive sleep apnoea is improved by a prolonged treatment of gastroesophageal reflux with omeprazole. *Dig Liver Dis* 2006;38(2):78-81.
5. Green BT, Broughton WA, O'Connor JB. Marked Improvement in Nocturnal Gastroesophageal Reflux in a Large Cohort of Patients with Obstructive Sleep Apnea Treated with Continuous Positive Airway Pressure. *Arch Intern Med* 2003;163(1):41-45.
6. Friedman M, Gurpinar B, Lin HC, Schalch P, Joseph NJ. Impact of treatment of gastroesophageal reflux on obstructive sleep apnea-hypopnea syndrome. *Ann Otol Rhinol Laryngol* 2007;116(11):805-811.
7. Benjafield AV, Ayas NT, Eastwood PR, et al. Estimation of the global prevalence and burden of obstructive sleep apnoea: a literature-based analysis. *Lancet Respir Med* 2019;7(8):687-698.